








## ORIGINAL ARTICLE

# Hyaluronic acid slows down collagen membrane degradation in uncontrolled diabetic rats

Meizi Eliezer<sup>1</sup>  | Anton Sculean<sup>1</sup>  | Richard J. Miron<sup>1</sup> | Carlos Nemcovsky<sup>2</sup>  |  
Evegeny Weinberg<sup>2</sup>  | Miron Weinreb<sup>3</sup> | Hasan Zoabi<sup>3</sup> | Dieter D. Bosshardt<sup>1,4</sup>  |  
Masako Fujioka-Kobayashi<sup>5</sup>  | Ofer Moses<sup>2</sup> 

<sup>1</sup>Department of Periodontology, School of Dental Medicine, University of Bern, Bern, Switzerland

<sup>2</sup>Department of Periodontology and Dental Implantology, The Maurice and Gabriela Goldschleger School of Dental Medicine, Tel Aviv University, Tel Aviv, Israel

<sup>3</sup>Department of Oral Biology, The Maurice and Gabriela Goldschleger School of Dental Medicine, Tel Aviv University, Tel Aviv, Israel

<sup>4</sup>Robert K. Schenk Laboratory of Oral Histology, School of Dental Medicine, University of Bern, Bern, Switzerland

<sup>5</sup>Department of Cranio-Maxillofacial Surgery, Inselspital, Bern University Hospital, University of Bern, Bern, Switzerland

## Correspondence

Meizi Eliezer, Department of Periodontology, School of Dental Medicine, University of Bern, Freiburgstrasse 7, CH-3010, Bern, Switzerland.  
Emails: meizi.eliezer@zmk.unibe.ch; meizi.eliezer@gmail.com

## Funding information

This study was partly supported by Regedent (Regedent, Zurich, Switzerland) who supplied the HA (hyaDENT) and the pericardial membranes (Smartbrane).

## Abstract

**Aim:** To examine the in vitro biokinetics of hyaluronic acid (HA) from a collagen membrane (CM) and to evaluate the in vivo effect of immersion of the CM in HA solution on its degradation in streptozotocin (STZ)-induced diabetes conditions in a rat calvaria subcutaneous model.

**Background:** CM degradation is accelerated in uncontrolled diabetic rats. Immersion of CM in HA has been suggested to decrease their resorption rate without interfering with their tissue integration and structural degradation. However, it is unknown to what extent CM degradation may be influenced by its immersion in HA solution under a condition mimicking a medically compromised situation with an increased inflammatory level such as diabetes.

**Materials and Methods:** CMs were soaked in cross-linked HA. Protein adsorption and the HA release were quantified by ELISA. Diabetes was induced in sixteen rats, while 16 healthy rats served as control. CM was prepared and labeled prior to implantation with Biotin. Seventeen CM were immersed in HA and 17 CM in PBS. In each animal, one test or one control disk was implanted. In order to compare the collagen content, two similar non-implanted CM were used as baseline. Fourteen days after surgery, thirty-two animals were sacrificed. The entire calvaria including the skin above, was chemically fixed, decalcified, and embedded in paraffin. Five- $\mu$ m-thick sections were analyzed histologically and histomorphometrically using H&E and avidin-peroxidase staining.

**Results:** The in vitro results demonstrated that the CM adsorbed roughly 80% of the total HA content. After 10 days, 36.3% of the initial HA remained on the CM. The in vivo results demonstrated that diabetes significantly reduced the thickness of the CM, while HA had a significant effect on keeping the membrane thickness. HA increased the residual collagen content in the diabetic group ( $P < 0.0001$ ) but no such effect was observed in the healthy group.

**Conclusion:** Immersion of CM in HA prior to the implantation delays membrane degradation in uncontrolled diabetic compared with normoglycemic rats.

## KEYWORDS

collagen membrane, diabetes mellitus, guided bone regeneration, hyaluronic acid

## 1 | BACKGROUND

Alveolar ridge augmentation by means of guided bone regeneration (GBR) has been shown to result in predictable bone formation with high long-term success rates.<sup>1-4</sup> Among the bioresorbable barriers, collagen membranes (CM) are frequently used for GBR procedures. Membranes create and maintain the space over the bony defect and act as a barrier against the ingrowth of epithelial and connective tissue cells into the defect.<sup>5</sup> Collagen membrane resorption occurs through a biodegradation process which starts when cells within the surgical site release matrix metalloproteinases (MMPs) into the wound area during healing and continues by fibroblast and blood vessel infiltration and colonization, leading to membrane degradation.<sup>5-7</sup> It has been shown that collagen membrane stability plays a crucial role in the success of regenerative procedures.<sup>8-11</sup> Premature exposure to the oral cavity is leading to early degradation and bacterial colonization compromising the beneficial effects of GTR or GBR procedures.<sup>10,12,13</sup> The degradation rate may be influenced by various parameters such as the composition, structure, and dimensions of the membrane<sup>5,6,10,14-16</sup> but also by systemic diseases, such as uncontrolled diabetes.<sup>17,18</sup> In recent studies, CM degradation was found to be accelerated in uncontrolled diabetic rats.<sup>17,18</sup> Moreover, the inflammatory infiltration of macrophages and capillaries from the tissues surrounding collagen membranes was more marked in diabetic rats compared to normoglycemic rats.<sup>17,18</sup> Enhanced degradation of collagen membranes in uncontrolled diabetic conditions may be correlated with existence of high cellular and molecular levels of inflammation. Therefore, new modalities aiming to reduce the amount of inflammation and slow down membrane degradation, especially in medically compromised patients such as uncontrolled diabetics, are warranted.

Hyaluronic acid (HA) is a natural glycosaminoglycan and an essential component of the skin and other connective tissues which plays an important role during wound healing.<sup>19</sup> HA is known as a hydrogel with inherent absorption properties involved in wound healing.<sup>19,20</sup> HA is biocompatible, biodegradable, bacteriostatic, antioxidant, and anti-edematous and shows anti-inflammatory properties.<sup>21-23</sup> It is used in various fields of medicine<sup>24</sup> and in dentistry.<sup>25</sup> Systematic reviews and meta-analyses have shown that HA has a beneficial effect when used in treating diabetes wound ulcers.<sup>26,27</sup> A possible explanation for these positive effects of HA on wound healing is the reduction in the cellular and molecular inflammatory burden, following its application to the wound<sup>26,27</sup> (ie, pad cream, substrate). A very recent systematic review has demonstrated favorable results using HA as an adjunct to periodontal surgical procedures.<sup>25</sup>

Immersion of CM in HA has been recently suggested as a novel approach aiming to decrease its resorption rate. This approach has

been shown not to interfere with tissue integration and structural degradation of various CMs.<sup>28</sup> However, at present, it is unknown to what extent CM degradation may be influenced by its immersion in HA solution under a condition mimicking a medically compromised situation with an increased inflammatory level such as diabetes.

Therefore, the aims of the study were as follows: (a) to examine the in vitro biokinetics of hyaluronic acid (HA) from a collagen membrane (CM) and, (b) to evaluate the in vivo effect of the immersion of the CM in HA solution on its degradation in streptozotocin (STZ)-induced diabetes compared with normoglycemic conditions in a rat calvaria subcutaneous model.

## 2 | MATERIAL AND METHODS

### 2.1 | In vitro part

Collagen membranes from porcine pericardium (Smartbrane; Regedent) were immersed in hyaluronic acid (HA; Regedent) utilizing a cross-linked carrier (hyaDENT BG; BioScience GmbH). HyaDENT BG (HA\_cl) contains 2.0 mg/mL of sodium hyaluronate and 16.0 mg/mL of sodium hyaluronate cross-linked with butanediol diglycidyl ether (BDDE).

Following immersion of the CM in HA gel, total adsorbed and released HA from the CMs was evaluated using 6-well culture dishes loaded with 0.3 mL of HA for a 5-minute coating period. All in vitro experiments were performed in triplicates with 3 independent experiments performed.

#### 2.1.1 | ELISA quantification of hyaluronic acid adsorption to barrier membranes

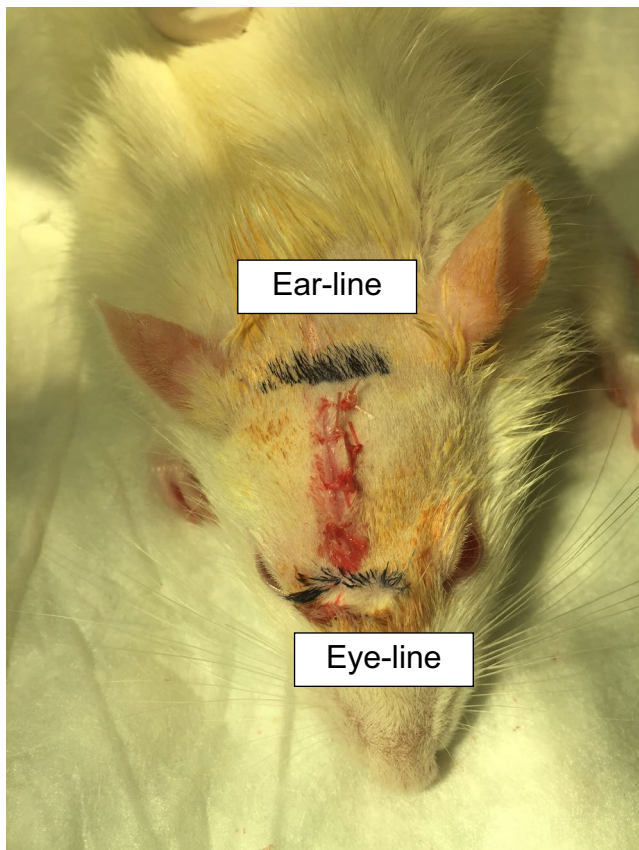To determine the quantity of HA adsorption to the surface of barrier membranes, ELISA quantification assay was utilized for HA. Briefly, after the coating period, incubation of 0.3 mL of HA onto 1 full-sized barrier membrane at 37°C, the remaining PBS solution, containing unattached HA was collected and quantified by a Quantikine Colorimetric Sandwich ELISA according to the manufacturer's protocol (R&D Systems). Thereafter, subtraction of total coated protein from the amount of un-adsorbed protein was used to determine the amount of adsorbed material to the surface of the barrier membranes as previously described.<sup>29</sup> Furthermore, in order to determine the quantity of HA being released from the barrier membranes over time, coated membranes were soaked in 5 mL of PBS in 6-well tissue culture dishes and samples were collected at various time points including 15 minutes, 1, 8 hours, 1, 3, and 10 days. All samples were quantified in triplicates and three independent experiments were performed.

## 2.2 | In vivo part

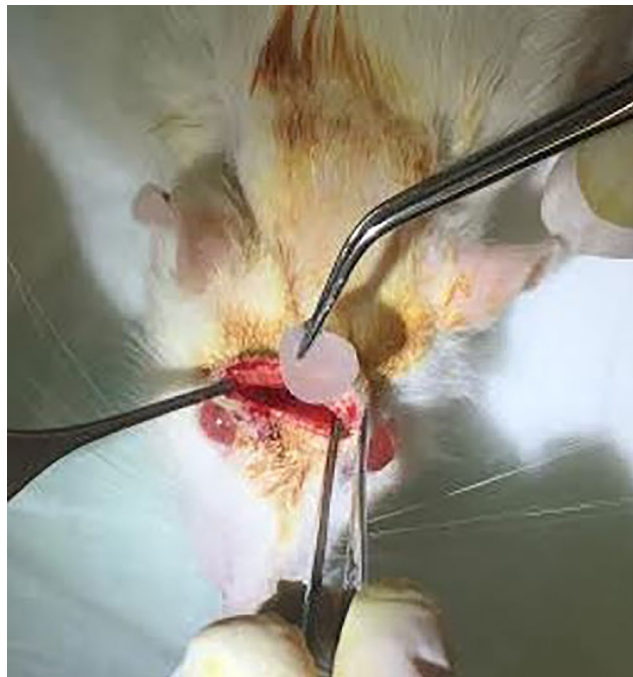The study comprised thirty-two 12-week-old male Wistar rats. The institution of Animal Care and Use Committee of Tel Aviv University, Tel Aviv, Israel, approved the study (TAU 01-16-031).

Diabetes was induced in sixteen rats by a single intraperitoneal (IP) injection of 65 mg/kg streptozotocin (Sigma Chemical Co.). Streptozotocin (STZ) is a naturally occurring alkylating antineoplastic agent that is particularly toxic to the insulin-producing beta cells of the pancreas in mammals, thus producing a state similar to type 1 diabetes in humans. The remaining animals were given similar volumes of citrate buffer and served as normoglycemic controls.

Pericardial CMs were cut with a disposable biopsy punch (Miltex Instrument Company) to 8-mm-diameter disks. Membrane labeling with biotin for detection of the collagen content of the membranes was carried out as described previously.<sup>17</sup> Briefly, all the disks (34) were labeled prior to implantation with 3 mg/mL of Aminohexanoyl-Biotin-N-Hydroxysuccinimide Ester (AH-BNHS; Zymed Laboratories) for one hour at room temperature and then washed overnight with three changes of phosphate-buffered saline (PBS) ( $\text{Ca}^{2+}$ - $\text{Mg}^{2+}$  free, pH 7.4) to remove any unbound biotin. Half of the biotin-labeled membrane disks (17 CMs) were immersed in a 20 mg/mL cross-linked-HA gel (Hyadent BG; Regedent AG) for one hour, followed by washing in PBS three times. We determined in vitro that adsorption of HA to the collagen membranes increased in a time-dependent pattern up to 1-hour immersion, no further



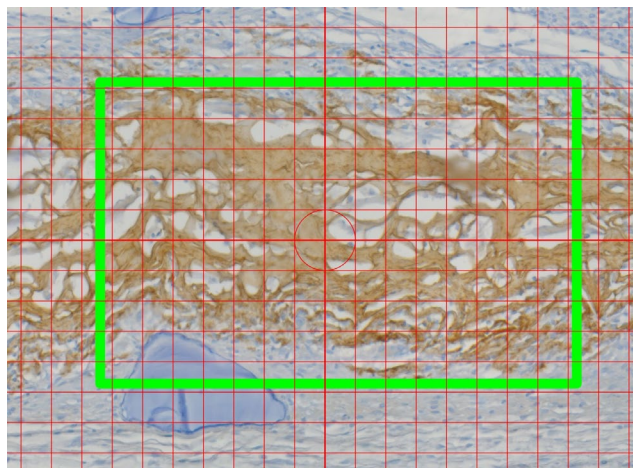
**FIGURE 1** Reference lines for reproducibility of the incision site



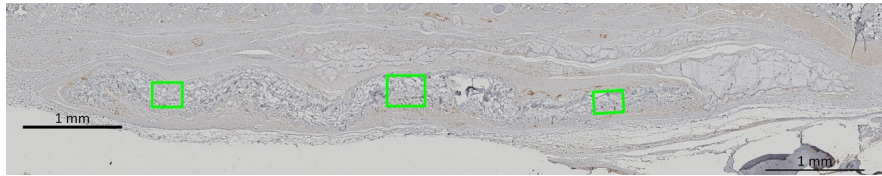
**FIGURE 2** Eight-millimeter diameter pericardial collagen disk is inserting to the “scalp pouch”

differences were recorded for longer immersion times. This in vitro evaluation was necessary since no preliminary data concerning the adsorption of HA to the collagen membranes were available. The remaining disks were immersed in PBS only.

All animal surgeries were performed by the same experienced operator (CN). The animals were anesthetized by intramuscular injection of 0.1 mL/100 g ketamine hydrochloride 10% and 0.1 mL/100 g xylazine hydrochloride 2% (Vitamed). The dorsal part of the skin covering the scalp was shaved and aseptically prepared for surgery. Two reference lines for reproducibility of the incision site were made by drawing a line between the ears (“ear-line”) and between the eyes (“eye-line”), then a line was marked in the mid-sagittal line between the “eye-line” and the “ear-line” (Figure 1). A



**FIGURE 3** Presentation of the Grid superimposed on the membrane ROI (magnification  $\times 100$ )



**FIGURE 4** Presentation of anterior, middle, and posterior ROI superimposed on the membrane (magnification  $\times 10$ )

15 mm incision was made vertically and perpendicularly toward a line between the eyes, beginning 5 mm away from line between the ears, on the mid-sagittal line. Following the incision, a subperiosteal pouch under the skin over the calvaria was created using a Kirkland periodontal knife (Hu-Friedy, Mfg. Co., LLC). One pericardial CM, immersed in HA or in PBS, was implanted in each animal underneath the periosteum (Figure 2). Periosteum and skin were repositioned, covering the implanted membrane, and the skin was sutured with resorbable sutures (VICRYL RAPIDE; Ethicon).

Fourteen days following surgery, animals were euthanized with an overdose of ketamine chlorohydrate (Rhone Merieux) at 90 mg/kg body weight and xylazine (Vitamed) at 10 mg/kg body weight, followed by asphyxiation with carbon dioxide ( $\text{CO}_2$ ). Dermal tissues were dissected together with the bone, leaving the scalp skin undisturbed covering the membrane disks. The calvaria and surrounding tissues were retrieved, fixed in 4% neutral buffered formalin, decalcified for 10 weeks in a 10% ethylenediaminetetraacetic acid (EDTA, pH 7.3) solution, washed, dehydrated in ethanol and xylene, and embedded in paraffin. Sagittal 5- $\mu\text{m}$  sections were made, and those that included the central area of the membrane were selected for comparative analysis of CM degradation. Some of the sections obtained were stained with hematoxylin and eosin (H&E) for histological analysis, and adjacent sections were stained with Horseradish peroxidase (HRP)-conjugated streptavidin (ZytoChem systems) according to the protocol of the manufacturer to detect biotinylated collagen. Briefly, slides were incubated with HRP-conjugated streptavidin solution of two drops for 30 minutes at room temperature, followed by detection with DAB substrate kit (ScyTek) and hematoxylin counterstain. All slides were mounted with an aqueous solution of glycerol vinyl alcohol (Zytomed).

Histological evaluation was performed by two investigators (DB, ME). Stained sections were photographed with a digital camera (AxioCam MRc; Carl Zeiss) mounted on a light microscope (AxioImager M2; Carl Zeiss) with a 20 $\times$  objective. Multiple digital scans were stored for each sample and analyzed for the thickness and residual collagen content of the membrane, skin, membrane voids and the gap between the membrane and the surrounding tissues.

A rectangle measuring 0.625 mm  $\times$  0.4 mm (0.25 mm<sup>2</sup>) was defined as a region of interest (ROI). This ROI was superimposed on three areas (anterior, middle, and posterior) of each disk on the histological section. A grid was superimposed on the ROI and the distance between the counting points was 40  $\mu\text{m}$ . The number of the counting points on the grid that hit the collagen, soft tissue and voids within the ROI were registered (Figure 3) using the ZEN pro 2012 software. Two non-implanted biotin-labeled disks (one immersed in HA and the other one in PBS) were processed the same way and served as baseline. Membrane thickness was measured in 3 pre-defined sites (anterior,

middle, and posterior) along the disks. The size of the gap between the membrane and the skin or the bone was measured in 3 different locations (anterior, middle, and posterior). In each slide, the mean of the measurements within each disk served as a unit for statistical analysis. Several slides from each specimen were also stained with hematoxylin and eosin to identify the surrounding tissues (Figure 4).

The sample size of the experiments was chosen to comply with a Type II error of 20% and expected effect size of 0.7.

The following parameters were evaluated by non-parametrical analysis (Kruskal-Wallis test) instead of ANOVA without assuming consistent standard deviation: (a) Membrane thickness, (b) Collagen area, (c) Soft tissue area, (d) Mean gap distance, and (e) Inside void space area. When the Kruskal-Wallis test was significant, two-stage step-up method of Benjamini, Krieger and Yekutieli post hoc test was performed for multiple comparisons. Results were considered statistically significant at  $P < 0.05$ . All statistic calculations were made by GraphPad Prism 7.0 software (GraphPad Software, Inc.).

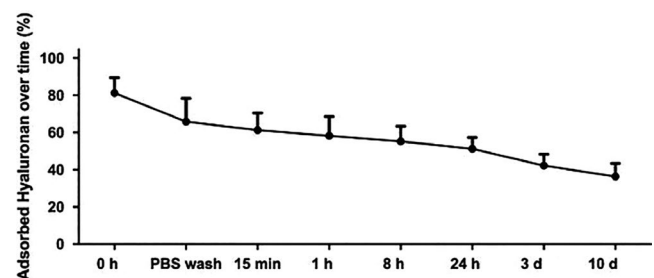
### 3 | RESULTS

#### 3.1 | In vitro

Adsorption to and release kinetics of HA from the collagen membranes was evaluated by an ELISA quantification assay (Figure 5). The porcine pericardium membranes adsorbed roughly 80% of the total HA within a 5-minute pre-coating period. These values decreased to 65% following a saline rinse with PBS. Thereafter, HA was gradually released over a 10-day period from 15 minutes in a controlled manner. After 15 minutes, 61.3% of the residual HA remained adsorbed on the collagen membrane and this decreased to 36.3% following a 10-day period (Figure 5).

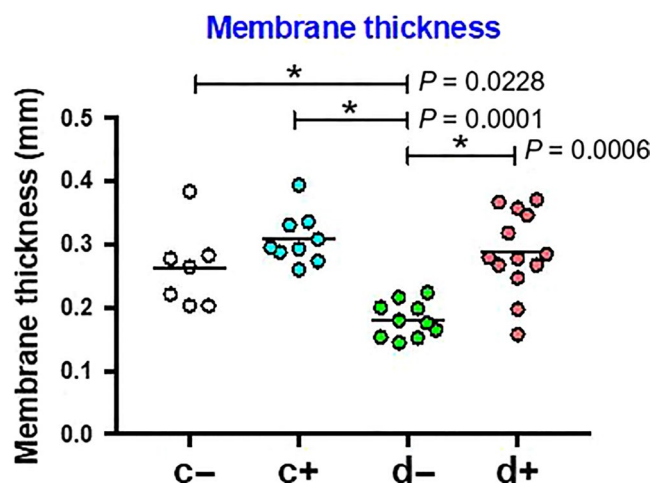
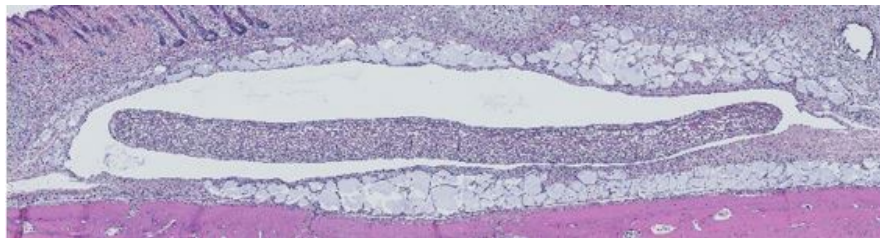
#### 3.2 | In vivo

All 16 STZ-injected rats demonstrated glucose level  $>200$  mg/dL after 5 days and, accordingly, were considered diabetic. Animals



**FIGURE 5** Adsorption to and gradual release kinetics of HA from the collagen membranes

**FIGURE 6** Histological evaluation with hematoxylin and eosin. HA appeared as amorphous or round light purple-bluish color (magnification  $\times 20$ )



**FIGURE 7** Membrane thickness measurements in millimeters showing that HA maintained membrane thickness when used in the diabetic rats (d+ group)

injected with citrate buffer did not develop diabetes and, therefore, served as a normoglycemic control group. Healing following the surgical procedure for the collagen disk implantation was uneventful in all animals. HA did not interfere with tissue integration and structural degradation of the pericardial collagen membrane.

After two weeks, HA was observed mostly outside the membrane or at the border of the membrane in all the histological sections of the control (c+) or the diabetic group (d+). The appearance of HA was amorphous with a round shape and light purple-bluish color (Figure 6).

The membrane thickness without HA immersion statistically significantly decreased in the diabetic group (d-) when compared to the control groups (c-/c+). There was no difference in membrane thickness between the control groups (c- vs c+), while the addition of HA to the diabetic group statistically significantly demonstrated higher membrane thickness (d- vs d+). There was no statistically significant difference between membrane thickness in the diabetic group with HA (d+) compared to the membranes in the control groups (c+/c-; Figure 7).

The area of residual collagen in PBS-immersed disks was lower compared with that of HA-immersed disks in diabetic rats at 2 weeks ( $30.02\% \pm 4.89$  vs.  $70.10\% \pm 10.71$  of baseline, respectively ( $P < 0.0001$ )). Immersion in HA significantly increased the area of residual collagen in diabetic but not in the normoglycemic animals (Figures 8, 9).

HA immersion decreased the soft tissue component in the membranes in both control and diabetic rats (c+ and d+). Especially, in

diabetic rats, HA treatment showed significantly lower percentage of soft tissue area in the membrane sites (d- vs d+). In other words, diabetes increased significantly the soft tissue component inside the PBS-immersed disks while the HA-immersed disks showed significantly less soft tissue component inside the membrane disks (d- vs d+;  $45\% \pm 8.89$  vs.  $19\% \pm 10.71$  of baseline, respectively [ $P < 0.0001$ ]) at 2 weeks (Figure 10).

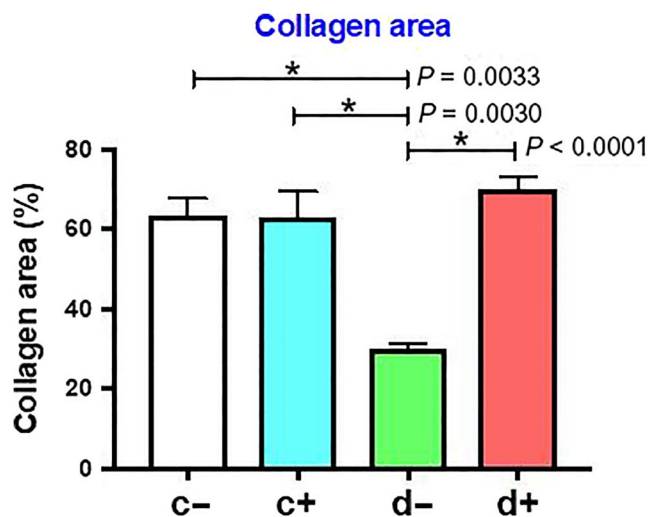
The gap between the collagen membrane and the surrounding bone or skin was wider in the two HA groups compared to the two groups without HA. The differences were, however, not statistically significant (Figures 11, 12).

Without HA, diabetic rats showed significantly higher percentage of internal membrane void area when compared to control rats (c- vs d-). HA immersion significantly decreased the membrane void area in diabetic rats (d- vs d+) but not in control rats (c- vs c+; Figure 13).

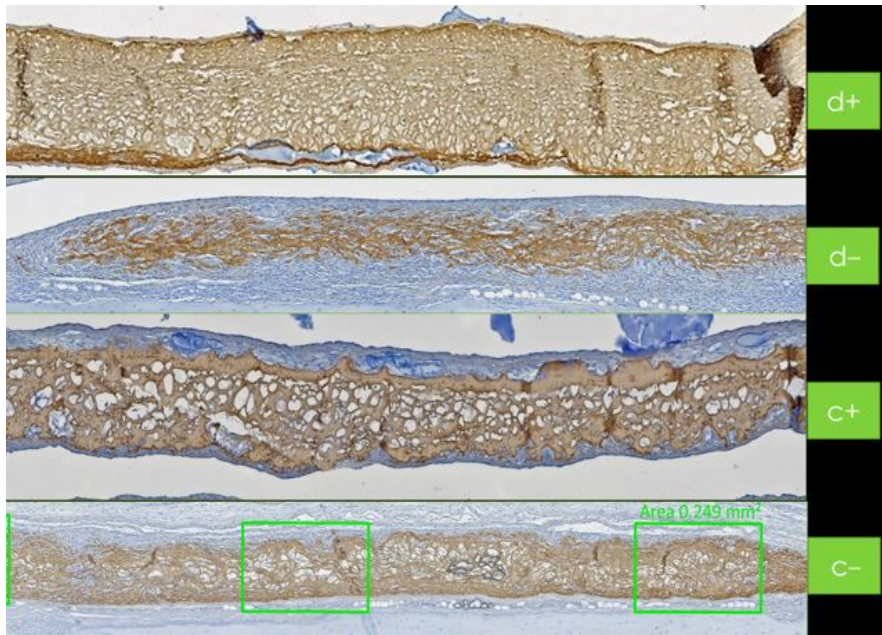
Comparison within the control groups revealed that HA had a reducing effect on the amount of soft tissue occupying the membrane and on keeping membrane thickness with collagen content, but this was not found to be statistically significant.

In the diabetic group, HA-immersed disks were 1.7-time thicker than PBS-immersed disks. The magnitude of the HA effect was invariably more pronounced in diabetic rats.

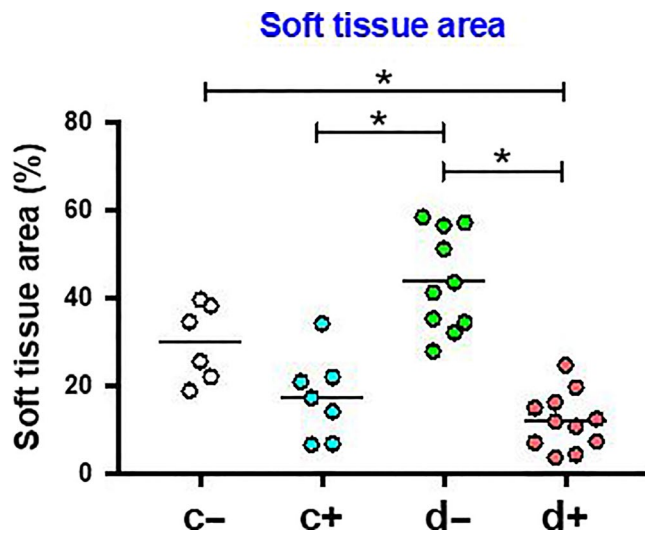
Although not measured microscopically, in the normoglycemic animals, no inflammatory infiltrate was observed around the membranes both in HA-immersed and PBS-immersed collagen disks.



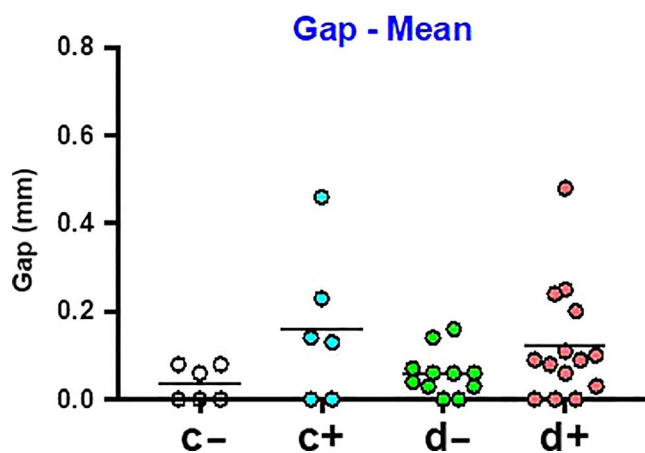
**FIGURE 8** Percentage of residual collagen area inside the ROI showing that adding HA to the membrane, contributed to better preservation of collagen content in the diabetic group



**FIGURE 9** Histological view of four collagen membranes stained in red/brown with Avidin-biotin-HRP reaction, 14 d after implantation in normoglycemic groups (C-/C+) or diabetic groups (d-/d+; magnification ×20)



**FIGURE 10** Percentage of soft tissue components area inside the membrane ROI



**FIGURE 11** Mean gap measurements in millimeters

However, a marked inflammatory infiltrate largely consisting of mononuclear cells was apparent within the tissue surrounding the PBS-immersed collagen membranes in the diabetic group, while the surrounding of the HA-immersed disk showed distinctly less inflammation very much like the normoglycemic group (Figures 14, 15).

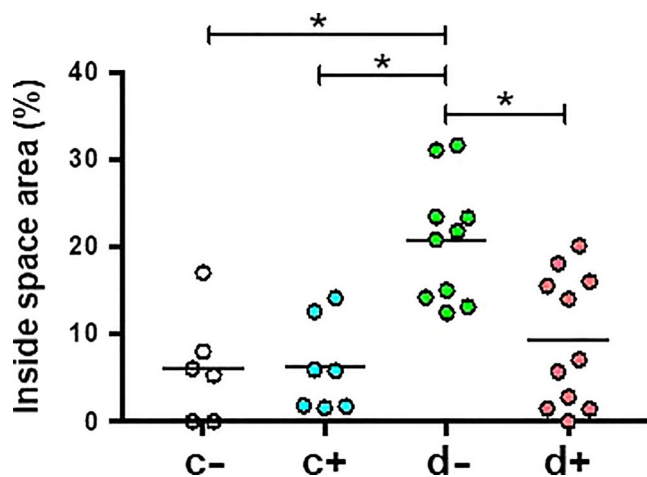
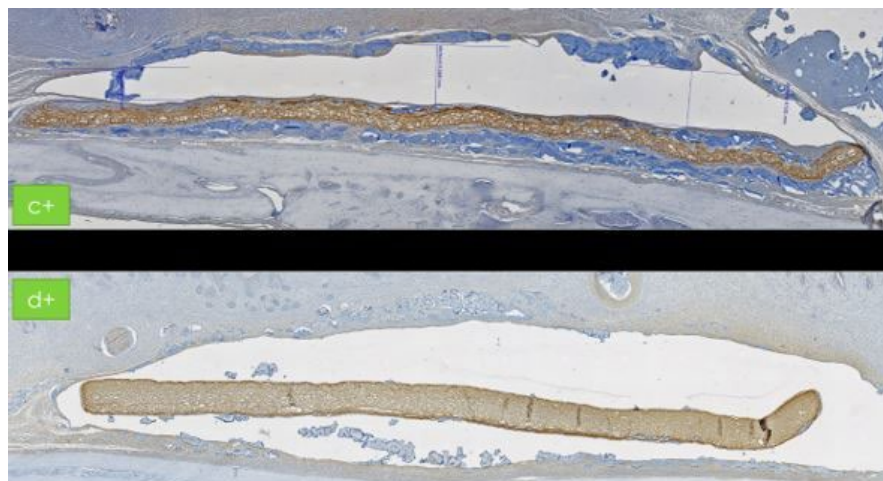
#### 4 | DISCUSSION

Collagen barrier membrane longevity plays a crucial role in the success of regenerative procedures.<sup>8-11,30</sup> The use of a barrier membrane is mandatory in GBR procedures, enabling unimpaired regeneration.<sup>31</sup> Collagen membrane degradation is carried out by the host's tissue inflammatory process. This phase is regulated by pro-inflammatory cytokines leading to the synthesis of matrix metalloproteinases (MMPs) by fibroblasts and inflammatory cells such as macrophages.<sup>32-34</sup>

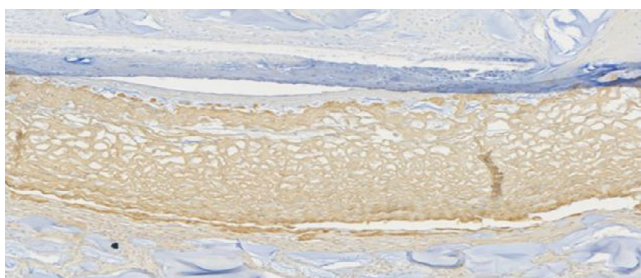
In uncontrolled diabetes, elevated oxidative stress and inflammation are evident.<sup>35</sup> Increased expression of MMPs has been observed in almost every inflammatory human disease. Scientific reports demonstrated that the level of MMPs is higher and the level of tissue inhibitors of metalloproteinases (TIMPs) is lower in uncontrolled diabetic conditions.<sup>36,37</sup> This could explain the enhanced degradation of CMs in uncontrolled diabetic rats as previously described.<sup>17,18</sup> Although the current study used a different source for the collagen membrane, this fact did not influence the tendency of the collagen membrane to degrade faster in STZ-induced uncontrolled diabetic rats. Cross-linked membranes have a much higher degradation time compared to native collagen membranes and therefore may show a different behavior in diabetic patients.

In the current and previous studies, the inflammatory cell infiltrate of the tissues surrounding the PBS-immersed CMs was more pronounced in the diabetic animals compared to the normoglycemic

**FIGURE 12** Histological view of gap measurements of two collagen membranes with HA stained in red/brown with Avidin-biotin-HRP reaction, 14 d after implantation in normoglycemic group (C+) or diabetic group (d+; magnification  $\times 10$ )



**FIGURE 13** Percentage of voids area inside membrane

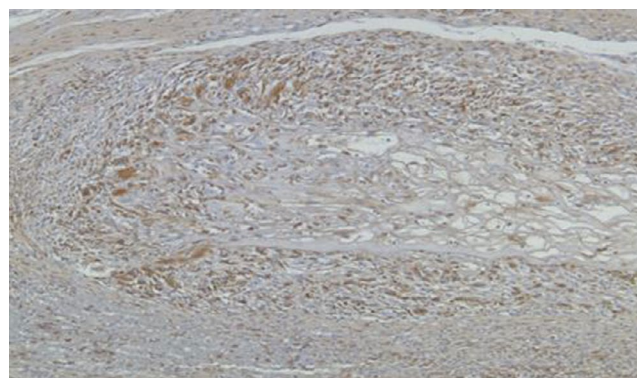


**FIGURE 14** Inflammatory infiltrate can hardly be noticed around and within the HA-immersed membrane in the diabetic animals. (staining: Biotin-streptavidine-HRP, magnification  $\times 40$ )

groups.<sup>17,18</sup> It may thus be anticipated that by reducing the inflammatory process with an anti-inflammatory adjuvant, the accelerated collagen membrane degradation may be slowed down.

HA is known as an anti-inflammatory and an antioxidant material.<sup>38,39</sup> A number of RCTs, systematic reviews, and meta-analyses have evaluated the effect of HA on chronic inflammation.<sup>26,27,38</sup>

However, to the best of our knowledge, currently, there are no studies measuring collagen membrane degradation following its immersion in HA in a preclinical *in vivo* study. The present animal study



**FIGURE 15** Marked inflammatory infiltrate, largely consisting of mononuclear cells, can be noticed around and within the PBS-immersed membrane in diabetic animals. (staining: Biotin-streptavidine-HRP, magnification  $\times 40$ )

was conducted to evaluate the effect of HA on the structural and biological properties and on degradation of a widely used pericardial collagen membrane.

Histological findings have shown that the immersion in a cross-linked HA gel did not interfere with the structure and degradation of the collagen membranes or soft tissue invasion into it. Our findings are in line with the results from another study in normoglycemic rats showing that HA did not interfere with tissue integration and structural degradation of collagen membranes.<sup>28</sup>

On one hand, the present study has shown that immersion in HA gel resulted in delayed degradation of the CM in uncontrolled STZ-induced diabetic rats. On the other hand, this effect was not demonstrated in the normoglycemic group, since HA- and PBS-immersed CMs showed no statistically significant differences regarding residual collagen membrane content and thickness. The fact that HA has an effect only on implanted collagen membranes in uncontrolled diabetic rats may be explained by the decrease in the magnitude of chronic inflammation typical in diabetic animals. Several studies showed that healing of diabetic wounds (ie, diabetic foot ulcers) is improved following the use of HA.<sup>27</sup> It has been previously demonstrated that in inflammatory situations, HA acts as a modulator to inflammation.<sup>26</sup> Such anti-inflammatory effects were

also demonstrated in two other in vitro studies.<sup>40,41</sup> Thus, it may be anticipated that the “modulating” effect of HA on the chronic inflammatory processes encountered in uncontrolled diabetes, resulted in decreased levels of MMPs which in turn delayed CM degradation.

Immersion of CMs in HA prior to implantation in STZ-induced uncontrolled diabetic rats has an inhibitory effect on membrane degradation and soft tissue cell invasion into it. In the present study, membranes were implanted subcutaneously under the scalp, which is a closed, extra-oral environment. Therefore, results cannot be directly compared with GBR/GTR procedures in the oral cavity, especially in cases where membranes may become exposed and contaminated. The use of high molecular weight HA to accelerate new bone formation in extraction sites was studied previously<sup>42</sup>; however, the possible effect of HA on bone formation is beyond the scope of our study. The in vitro part of this study demonstrated that HA is adsorbed to the CM and slowly released into the surrounding medium. This may lead to a theoretical understanding that HA will be released from the CM in a slow release mode, also to the surrounding tissues potentially assisting in delaying membrane degradation in uncontrolled diabetes. However, further studies are necessary to explore the delaying mechanism of HA-immersed CMs on the inflammatory cells and to explore the clinical relevance of these findings.

## ACKNOWLEDGEMENTS

The authors wish to thank Hanna Vered (Tel Aviv, Israel), Owusu Silvia, Thuy-Trang Nguyen and Monika Aeberhard (Bern, Switzerland), who kindly provided their technical and laboratory work expertise.

## CONFLICTS OF INTEREST

The authors declare that there are no conflicts of interest in this study.

## ORCID


Meizi Eliezer  <https://orcid.org/0000-0003-2164-1272>

Anton Sculean  <https://orcid.org/0000-0003-2836-5477>

Carlos Nemcovsky  <https://orcid.org/0000-0002-5087-6145>

Evegeny Weinberg  <https://orcid.org/0000-0002-8010-8921>

Dieter D. Bosshardt  <https://orcid.org/0000-0002-2132-6363>

Masako Fujioka-Kobayashi  <https://orcid.org/0000-0002-1511-9085>

Ofer Moses  <https://orcid.org/0000-0003-1396-6501>

## REFERENCES

- Jovanovic SA, Spiekermann H, Richter EJ. Bone regeneration around titanium dental implants in dehiscence defect sites: a clinical study. *Int J Oral Maxillofac Implants.* 1992;7:233-245.
- Simion M, Jovanovic SA, Trisi P, Scarano A, Piattelli A. Vertical ridge augmentation around dental implants using a membrane technique and autogenous bone or allografts in humans. *Int J Periodontics Restorative Dent.* 1998;18:8-23.
- Zitzmann NU, Naef R, Scharer P. Resorbable versus nonresorbable membranes in combination with Bio-Oss for guided bone regeneration. *Int J Oral Maxillofac Implants.* 1997;12:844-852.
- Jung RE, Fenner N, Hammerle CH, Zitzmann NU. Long-term outcome of implants placed with guided bone regeneration (GBR) using resorbable and non-resorbable membranes after 12-14 years. *Clin Oral Implants Res.* 2013;24:1065-1073.
- Rothamel D, Benner M, Fienitz T, et al. Biodegradation pattern and tissue integration of native and cross-linked porcine collagen soft tissue augmentation matrices - an experimental study in the rat. *Head Face Med.* 2014;10:10.
- Rothamel D, Schwarz F, Sager M, Herten M, Sculean A, Becker J. Biodegradation of differently cross-linked collagen membranes: an experimental study in the rat. *Clin Oral Implants Res.* 2005;16:369-378.
- Willershausen I, Barbeck M, Boehm N, et al. Non-cross-linked collagen type I/III materials enhance cell proliferation: in vitro and in vivo evidence. *J Appl Oral Sci.* 2014;22:29-37.
- Patino MG, Neiders ME, Andreato S, Noble B, Cohen RE. Collagen as an implantable material in medicine and dentistry. *J Oral Implantol.* 2002;28:220-225.
- Pfeifer J, Van Swol RL, Ellinger R. Epithelial exclusion and tissue regeneration using a collagen membrane barrier in chronic periodontal defects: a histologic study. *Int J Periodontics Restorative Dent.* 1989;9:262-273.
- Tal H, Kozlovsky A, Artzi Z, Nemcovsky CE, Moses O. Long-term bio-degradation of cross-linked and non-cross-linked collagen barriers in human guided bone regeneration. *Clin Oral Implants Res.* 2008;19:295-302.
- Chung KM, Salkin LM, Stein MD, Freedman AL. Clinical evaluation of a biodegradable collagen membrane in guided tissue regeneration. *J Periodontol.* 1990;61:732-736.
- Zitzmann NU, Scharer P, Marinello CP. Long-term results of implants treated with guided bone regeneration: a 5-year prospective study. *Int J Oral Maxillofac Implants.* 2001;16:355-366.
- Machtei EE. The effect of membrane exposure on the outcome of regenerative procedures in humans: a meta-analysis. *J Periodontol.* 2001;72:512-516.
- Karring T, Nyman S, Gottlow J, Laurell L. Development of the biological concept of guided tissue regeneration-animal and human studies. *Periodontol 2000.* 1993;1:26-35.
- Ferreira AM, Gentile P, Chiono V, Ciardelli G. Collagen for bone tissue regeneration. *Acta Biomater.* 2012;8:3191-3200.
- Bozkurt A, Apel C, Sellhaus B, et al. Differences in degradation behavior of two non-cross-linked collagen barrier membranes: an in vitro and in vivo study. *Clin Oral Implants Res.* 2014;25:1403-1411.
- Eliezer M, Nemcovsky C, Romanos G, et al. Opposing effects of diabetes and tetracycline on the degradation of collagen membranes in rats. *J Periodontol.* 2013;84:529-534.
- Moses O, Eliezer M, Nemcovsky C, Tal H, Weinreb M. Accelerated degradation of collagen membranes in diabetic rats is associated with increased infiltration of macrophages and blood vessels. *Clin Oral Investig.* 2016;20:1589-1596.
- Croce MA, Dyne K, Boraldi F, et al. Hyaluronan affects protein and collagen synthesis by in vitro human skin fibroblasts. *Tissue Cell.* 2001;33:326-331.
- Alexander SA, Donoff RB. The glycosaminoglycans of open wounds. *J Surg Res.* 1980;29:422-429.
- Campo GM, Avenoso A, D'Ascola A, et al. Inhibition of hyaluronan synthesis reduced inflammatory response in mouse synovial fibroblasts subjected to collagen-induced arthritis. *Arch Biochem Biophys.* 2012;518:42-52.



22. Pirnazar P, Wolinsky L, Nachnani S, Haake S, Pilloni A, Bernard GW. Bacteriostatic effects of hyaluronic acid. *J Periodontol*. 1999;70:370-374.
23. Fraser JR, Laurent TC, Laurent UB. Hyaluronan: its nature, distribution, functions and turnover. *J Intern Med*. 1997;242:27-33.
24. Robert L. Hyaluronan, a truly "youthful" polysaccharide. Its medical applications. *Pathol Biol (Paris)*. 2015;63:32-34.
25. Bertl K, Bruckmann C, Isberg PE, Klinge B, Gotfredsen K, Stavropoulos A. Hyaluronan in non-surgical and surgical periodontal therapy: a systematic review. *J Clin Periodontol*. 2015;42:236-246.
26. Chen WY, Abatangelo G. Functions of hyaluronan in wound repair. *Wound Repair Regen*. 1999;7:79-89.
27. Voigt J, Driver VR. Hyaluronic acid derivatives and their healing effect on burns, epithelial surgical wounds, and chronic wounds: a systematic review and meta-analysis of randomized controlled trials. *Wound Repair Regen*. 2012;20:317-331.
28. Silva EC, Omonte SV, Martins AG, et al. Hyaluronic acid on collagen membranes: an experimental study in rats. *Arch Oral Biol*. 2017;73:214-222.
29. Miron RJ, Bosshardt DD, Buser D, et al. Comparison of the capacity of enamel matrix derivative gel and enamel matrix derivative in liquid formulation to adsorb to bone grafting materials. *J Periodontol*. 2015;86:578-587.
30. Tal H, Kozlovsky A, Artzi Z, Nemcovsky CE, Moses O. Cross-linked and non-cross-linked collagen barrier membranes disintegrate following surgical exposure to the oral environment: a histological study in the cat. *Clin Oral Implants Res*. 2008;19:760-766.
31. Wessing B, Urban I, Montero E, et al. A multicenter randomized controlled clinical trial using a new resorbable non-cross-linked collagen membrane for guided bone regeneration at dehiscence sites: interim results of a bone augmentation procedure. *Clin Oral Implants Res*. 2017;28:e218-e226.
32. Young PK, Grinnell F. Metalloproteinase activation cascade after burn injury: a longitudinal analysis of the human wound environment. *J Invest Dermatol*. 1994;103:660-664.
33. Mauviel A. Cytokine regulation of metalloproteinase gene expression. *J Cell Biochem*. 1993;53:288-295.
34. Bennett NT, Schultz GS. Growth factors and wound healing: biochemical properties of growth factors and their receptors. *Am J Surg*. 1993;165:728-737.
35. Giacco F, Brownlee M. Oxidative stress and diabetic complications. *Circ Res*. 2010;107:1058-1070.
36. Yang C, Zhu P, Yan L, Chen L, Meng R, Lao G. Dynamic changes in matrix metalloproteinase 9 and tissue inhibitor of metalloproteinase 1 levels during wound healing in diabetic rats. *J Am Podiatr Med Assoc*. 2009;99:489-496.
37. Han SY, Jee YH, Han KH, et al. An imbalance between matrix metalloproteinase-2 and tissue inhibitor of matrix metalloproteinase-2 contributes to the development of early diabetic nephropathy. *Nephrol Dial Transplant*. 2006;21:2406-2416.
38. Salwowska NM, Bebenek KA, Zadlo DA, Wcislo-Dziadecka DL. Physicochemical properties and application of hyaluronic acid: a systematic review. *J Cosmet Dermatol*. 2016;15:520-526.
39. Ke C, Sun L, Qiao D, Wang D, Zeng X. Antioxidant activity of low molecular weight hyaluronic acid. *Food Chem Toxicol*. 2011;49:2670-2675.
40. Presti D, Scott JE. Hyaluronan-mediated protective effect against cell damage caused by enzymatically produced hydroxyl (OH) radicals is dependent on hyaluronan molecular mass. *Cell Biochem Funct*. 1994;12:281-288.
41. Kvam BJ, Fragonas E, Degraffi A, et al. Oxygen-derived free radical (ODFR) action on hyaluronan (HA), on two HA ester derivatives, and on the metabolism of articular chondrocytes. *Exp Cell Res*. 1995;218:79-86.
42. Sasaki T, Watanabe C. Stimulation of osteoinduction in bone wound healing by high-molecular hyaluronic acid. *Bone*. 1995;16(1):9-15.

**How to cite this article:** Eliezer M, Sculean A, Miron RJ, et al. Hyaluronic acid slows down collagen membrane degradation in uncontrolled diabetic rats. *J Periodontol Res*. 2019;00:1-9. <https://doi.org/10.1111/jre.12665>